

---

---

# CASE STUDY

---

---

## Resolution of Hypertension Following Reduction of Upper Cervical Vertebral Subluxation: A Case Study

*Jonathan Chung D.C.<sup>1</sup>, Justin Brown D.C.<sup>2</sup>, Joseph Busa D.C.<sup>3</sup>*

---

### ABSTRACT

**Objective:** The evaluation of hypertension for a patient before and after the start of upper cervical chiropractic care specifically with NUCCA (The National Upper Cervical Chiropractic Association) technique adjustments and its associated effects on blood pressure are examined. It is the aim of this paper to support the findings of the Pilot Study conducted by Bakris and Dickholtz, and to provide a brief explanation of the mechanisms behind this phenomena.

**Clinical Features:** A male patient presents with sciatica, wrist pain and hypertension which he has been treating with the medication Lisinopril and Simvastatin. It was found that he exhibited postural changes, uneven weight distribution, thermograph asymmetries and x-ray findings that substantiated adjustments to the first cervical vertebra according to the NUCCA chiropractic technique analysis.

**Intervention and Outcomes:** Contact specific, low force adjustments (NUCCA) to the upper cervical area of the spine were performed. Throughout care, the patient noted decreases in his sciatica pain, wrist pain and decreases in his blood pressure. After 16 adjustments, the patient is no longer taking medications to control his hypertension and his blood pressure remains stable.

**Conclusions:** All of the patient symptoms improved with chiropractic adjustments to the first cervical vertebra. Repeatable findings that chiropractic care can regulate blood pressure to desirable levels would be a push in the right direction to substantiate the validity of chiropractic care in helping patients with more than just neck pain, low back pain and headaches.

**Key Indexing Terms:** *Hypertension, chiropractic, vertebral subluxation, blood pressure, NUCCA*

---

### Introduction

37 billion dollars is spent annually on treatment for hypertension which is an important public health concern.<sup>1</sup> According to the World Health Organization (WHO), hypertension is the most common cause of preventable death in developed countries<sup>2</sup> and it is a major risk factor for cardiovascular conditions such as heart attacks and

strokes which are the first and third leading cause of death in the US.<sup>3</sup>

This is a very serious public health concern and what's worse is that the prevalence of hypertension in the US is increasing - especially amongst non-Hispanic black women and the elderly populations. Though the actual rate is unknown, in the year

- 
1. Private Practice of Chiropractic, Wellington, FL
  2. Private Practice of Chiropractic, Coral Springs, FL
  3. Private Practice of Chiropractic, Littleton, CO

2000 it was estimated that about 29% of the adult US population (approximately 60 million individuals) had hypertension<sup>4</sup> and it may affect as many as one billion people worldwide and cause as many as 7.1 million deaths each year.<sup>5</sup>

Traditionally, the treatment method of choice has been through the use of anti-hypertensive medication. Considering that anti-hypertensive medication has been on the market since the 1950s<sup>3</sup> and the usage of said medication has increased over the years<sup>1</sup> and the incidence of hypertension is also increasing with no signs showing a decrease in any subgroup of people; the current prevention methods appear to be unsuccessful and we should start looking for alternative methods of treatment.<sup>6</sup>

One such alternative that warrants a closer look is chiropractic adjustments to the first cervical vertebra (referred to as C1 or the Atlas vertebra) which has been associated with reducing arterial blood pressure to the equivalent of two-drug combination therapies in patients.<sup>7</sup>

## Case Report

### *Patient History*

The patient is a 57 year old male who presented complaining of sciatica for 1.5 years, bilateral wrist pain for two years and high blood pressure for 5 years. He described the sciatica pain as “sharp” and it is made worse with activity. His wrist pain prevented him from being as active as he'd like. He was treating his hypertension with the medications Lisinopril and Simvastatin. He is an engineer that works 5-6 hour days sitting behind a computer. He stated he exercises about 1 day each week. About 10 years ago he was involved in a motor vehicle accident (MVA) where a car traveling 10 mph rear ended him. He sustained no injuries and was not treated. About 5 years ago he was involved in another rear-ended MVA when a car traveling 2-5 mph slid into his car.

### *Examination*

Assessment of the patient using the NUCCA technique was applied and the following postural distortions were found: 3/8” short left leg, right head tilt, 1” low left shoulder and 1” low right hip. Weight distribution measured 86.5 lbs on the right and 66 lbs on the left. Palpation revealed C1 right fixation, hypertonicity in the sub-occipital region and over C2-C4, right levator scapula strain and edema in the left sacroiliac joint. Cervical x-rays were obtained and measured for Atlas listing. The adjustment vector was determined as right Atlas, high 1/5 inches, anterior 5.25 inches requiring a clockwise torque and contact point 1/4” below palpable mastoid. The pre-nasium (Figure 1) film when measured determined Atlas laterality to the right by 2.75 degrees, head tilt 1.72 degrees, and lower angle left 1.45 degrees. Pre-vertex film (Figure 2) demonstrated the Atlas was rotated anterior by 5.1 degrees. Blood pressure measured 150/90 mm Hg.

### *Intervention*

The patient received his first cervical adjustment as was indicated based on postural deviations, leg length, decreased cervical range of motion and musculoskeletal inequality. The Atlas was adjusted and on post check the legs had balanced

and motion of the neck improved. The patient came back to the office each week and received an adjustment.

### *Outcome*

By the 8th visit to the clinic the patient had no neurological or musculoskeletal findings, discrepancies in leg length and thermographic scan of the neck demonstrated equality in heat. The patient did not receive an adjustment on this visit. The following week the patient demonstrated requirements for an adjustment.

Upon his re-exam date, he noted that his blood pressure improved approximately 70% as compared to his initial presentation. The other symptoms improved also. Sciatica by 90% and the wrist pain by 70% also.

The patient was adjusted 8 more times before his second re-exam, approximated two months later. It was noted that his blood pressure had improved 100% and he decided to remove himself off his prescriptions for hypertension. He continues to have blood pressure between 120-130/80-90 mm Hg qualifying him as having pre-hypertension to normal blood pressure. He also reports that his sciatica has improved 100% and his wrist pain improved 60%. The patient decided to continue his care.

Post-nasium (Figure 3) x-ray indicated Atlas laterality improved 73%, measuring 0.74 degrees. There was also a 100% reduction in his head tilt and lower angle measured 0.33 degrees left, a 77% reduction. The post-vertex (Figure 4) film shows the anterior rotation of the Atlas as 5.67 degrees - a 0.6 degree increase.

### *NUCCA technique*

NUCCA, an upper cervical chiropractic adjusting technique was founded by Ralph Gregory D.C. in 1966. To establish criteria for an adjustment of the Atlas vertebra, the assessment criteria set forth by the NUCCA technique requires that the patient lay supine so that the doctor can check for leg length disparities. These are caused by Atlas misalignments. Then the patient is asked to turn the head towards the left and then to the right as the doctor checks for changes in the length of the legs.

Another component of the NUCCA analysis is the use of a device called the 'Anatometer' which was developed by Benesh Corp. The 'Anatometer' provides diagnostic details of postural asymmetries. Left and right weight scales and other calibration mechanisms such as degree of pelvic distortions between the iliac crests and soles of the feet in the frontal, transverse and horizontal planes and lateral spinal-column displacement at C7 or T1 with head tilt. And finally, three x-ray views (lateral cervical, nasium and vertex) are also used to aid the doctor in appropriately and specifically measuring the degree and direction of the Atlas misalignment.

Analysis from the x-rays is conducted as follows: physiological landmarks are located by the doctor and a 'vertical axis line' which denotes perfect Atlas placement, is drawn with a pencil along with a pencil mark at the center of the skull on the nasium film. A protractor is used to measure

physiologic angles, view by view in order to paint a three-dimensional picture of Atlas' degree and orientation. All of these measurements are carried out initially as baseline and repeated after the first visit and again after 8 weeks of care.

The adjustment uses a low (8-inch) side posture table with patient position dependent on the misalignment of the Atlas vertebra. The patient's head is placed on a solid, curved mastoid/ skull supportive headpiece that serves as the adjustments 'fulcrum'. The segmental contact is over the C1 transverse process via the doctor's pisiform on the dominant hand. The force (which is a combination of a series of precise, subtle nudges) is placed into a specific, pre-calculated vector generated by a triceps pull resetting the occipital condyles into the Atlas' lateral masses.<sup>7,8</sup>

## Discussion

To be diagnosed with hypertension you need to have a resting systolic blood pressure  $\geq 140$  mmHg over diastolic blood pressure  $\geq 90$  mmHg. Hypertension used to be considered as having blood pressure  $\geq 160/90$  mmHg before it was reduced to its current level.<sup>2</sup> Pre-hypertension is between 120-129/80-89 mmHg while normal healthy blood pressure levels are considered 120/80 mmHg.<sup>4</sup>

As stated earlier in the report, the prevalence of hypertension is on the rise and so is the use of anti-hypertensive medication. Several factors are responsible for causing the rise of hypertension and this paper will address some of those causes and propose that misalignment of C1 as another potential risk factor.

First, it's important to understand several of the mechanisms in the body that have been shown to affect arterial blood pressure and thanks to the developments and advancements in technologies in neuroscience since the 1950's, our understandings of neuroanatomy, neurochemistry and physiology within the pathways of the brain and its role in maintaining normal levels of arterial blood pressure have improved significantly. We now know that the brain governs the tonic and baroreflex controls of vasculature and has an effect on blood pressure via observations that agitations in those networks can cause or reverse hypertension.<sup>9</sup> How exactly does the brain play a role in hypertension? To fully answer that question is beyond the scope of this paper however, the information provided should suffice as an adequate answer which (as it is our intention) would satisfy most readers.

Over the years, evidence has been able to demonstrate that a zone of the medulla oblongata called the rostral ventrolateral quadrant (RVL) functions as a tonic vasomotor center. Inhibitory neurotransmitters to the RVL have been shown to lower arterial blood pressure.<sup>10</sup>

Experiments done on anesthetized cats were able to demonstrate that when the drug Leptazol was applied uni- or bilaterally to the ventral surface of the medulla (around cranial nerve XII), inhibition of sympathetic vasomotor tone produced hypotension. Other studies have shown that the medulla has at least two distinct areas with different effects on blood pressure. The more inferior 'glycine-sensitive' area has been

shown to be imperative for the maintenance of arterial blood pressure and the more superior 'nicotine-sensitive' area was shown to influence the secretion of vasopressin (a small peptide molecule secreted by the pituitary gland that is an antidiuretic hormone) that lowered blood pressure when nicotine was applied.<sup>11</sup> These observations indicated that there are neurons close to the RVL of the medulla that provide a tonic/ excitatory drive to the spinal sympathetic outflow which maintains a normal level of resting blood pressure.<sup>11,12</sup>

Another cause of hypertension came from a study in 1978 and 1992 that found that neurovascular/pulsatile compression of the ventrolateral medulla oblongata causing permanent irritation and activation of the vasopressor neurons located there. This was done by the use of magnetic resonance imaging (MRI). A 1.5-T superconducting magnet and circularly polarized head coil was used to provide three-dimensional fast low angle images at the pontomedullary junction to evaluate the relationships between the upper ventrolateral medulla and the branches associated with the vertebral artery on 32 patients.

The results showed that 90.6% had neurovascular compression on the medulla from the vertebral artery and smaller branches i.e. the posterior inferior cerebellar artery on the left side. It is uncertain as to why there is a prevalence on the left. It was also found that neurovascular compression of the vagus nerve can cause a blockade of cardiac C-fibers which causes a rise in blood pressure.<sup>13</sup>

A survey of non-institutionalized United States citizens called NHANES study (The National Health and Nutrition Examination Survey), collected data from its' participants regarding their age, race, weight and height and body mass index (BMI) were calculated. The results of this survey raised suspicions that increasing rates of obesity and BMI correlated with increasing rates of hypertension and is believed to be a contributing risk factor. The increases in obesity rates and BMI values highlights the urgent need for more preventative interventions that can be introduced to control these rates of hypertension.<sup>4,6</sup>

Another important risk factor for hypertension is age. It is estimated that about two thirds out of US adults over 75 years old suffer from hypertension.<sup>2</sup> As we age, alterations in the tunica media and intima layers of the arterial walls occur which causes endothelial dysfunction. Endothelial cells play a critical role in regulating properties of arteries such as releasing nitric oxide (NO). Nitric oxide is a multifunctional molecule that stimulates vasodilation between the cells that make up the microvascular environment. Also as a result of aging, there is an increase of free radicals which can affect NO therefore affecting hypertension. Increased myogenic constriction, shortening of the telomeres and endothelial progenitor cells have been noted to play a part in hypertension.<sup>6</sup>

So what can people do to treat hypertension? One route many have taken is controlling blood pressure with medications. People have been using anti-hypertensive medication since the 1950s. The first to be approved by the FDA (US Food and Drug Administration) was Thiazide followed by  $\beta$ -blockers in 1962 and then  $\alpha$ -blockers in 1967. Calcium channel blockers

and angiotensin-converting enzyme (ACE's) inhibitors became available in 1982 and 1984 followed by Angiotensin II receptor blockers or ARB's in 1995.<sup>3</sup> Throughout the past 70 years, the amount of medication to treat hypertension has increased along with the amounts that patients consume. It is estimated that approximately \$37 billion dollars are spent annually for not just the medications; but for office visits and lab tests for hypertension.<sup>1</sup>

Chiropractic care to the upper cervical spine has been shown to cause a reduction in hypertension without the use of medication. Incidentally, the patients were able to wean themselves off their hypertension medications entirely and their blood pressure was able to remain normal.<sup>7</sup> One method to explain this is the axons of the adrenergic neurons of C1 ascend dorsally through the medulla contributing to the ascending and descending limbs of the principle tegmental adrenergic bundle a major fiber tract. It is the descending limb that appears to be of major importance in cardiovascular regulation since these fibers project directly to the thoracic and lumbar spinal cord.<sup>10</sup> Other studies demonstrated a closely knit correspondence between the location of C1 neurons in the RVLM and sites at which chemical or electrical stimulation increases blood pressure and sympathetic vasomotor activity.<sup>14</sup>

These early observations led to the view that the C1 neurons are sympathoexcitatory and have a critical role in the tonic and reflex control of sympathetic vasomotor activity. However, in a paper published in *The Journal of Physiology*, other observations have raised some doubt on this view of the functions of C1 neurons in sympathetic regulation. A significant proportion (about 1/3) of neurons in the RVLM that project directly to the spinal sympathetic outflow are not C1 cells. Perhaps those non-C1 cells, rather than C1 cells, are largely responsible for the regulation of sympathetic vasomotor activity by RVLM neurons.<sup>12</sup> It is still uncertain as to why correction of the Atlas vertebra results in improved blood pressure. Perhaps misalignment of C1 should be considered an additional risk factor to the development of hypertension.<sup>7</sup>

Recent neuroscience research, supports a neurophysiological rationale for the concept that aberrant stimulation of spinal or paraspinal structures may lead to segmentally organized reflex responses of the autonomic nervous system (ANS) which in turn, may alter visceral function<sup>15</sup> since the Atlas relies predominantly on soft tissues like muscles, tendons and ligaments to maintain its' proper alignment<sup>7</sup> this could be one explanation why.

Some concerns regarding negative consequences of upper cervical adjustments like stroke or VAD (vertebral artery dissections) are prevalent among the scientific community. However, it was found that the risks of having a stroke caused by a chiropractor vs a general medical practitioner were practically equal. This suggests that cervical manipulation are not a cause of cerebrovascular accidents, but may be associated with a stroke already in progress and should not deter people from seeking chiropractic care.<sup>16</sup>

This does not mean however there are no risks associated with upper cervical chiropractic care as there may be a fairly

common occurrence of mild intensity symptomatic reactions (SRs) that are short in duration (<24 hours) and rarely severe in intensity. Although this is less severe than a stroke or VAD, it's important to emphasize that with less than three weeks of care, outcome assessment tools among patients surveyed improved significantly and overall showed high levels of patient satisfaction. Those findings are limited and need to be confirmed in subsequent randomized studies for definitive risk vs. benefits assessment. The preliminary data shows that the benefits of upper cervical chiropractic care outweigh the potential risks.<sup>8</sup>

## Conclusion

This paper just scratches the surface of the various mechanisms that can influence blood pressure in individuals. This paper focused more on the brain stem and medulla and their influence over hypertension as the location of these organs are quite near to the Atlas vertebra. Since it is close in proximity, this could explain why misalignments of the Atlas cause distortions to the tracts of the spinal cord that ascend to the medulla resulting in hypertension. This case supports this conclusion and the improvements are consistent with the findings in the pilot study conducted by Bakris.<sup>7</sup>

Since hypertension is a growing health concern for the public and billions are spent annually, the findings presented in this paper help support the role of chiropractic management beyond pain syndromes. This could just be the type of healthy lifestyle intervention that is needed.<sup>4</sup> More conclusive evidence would greatly help shift the medical paradigm and offer alternatives to medications and allopathic treatments and help spawn the search for other ailing conditions that affect millions of people worldwide that can be managed naturally through subluxation reduction and correction.

There are some limitations to the case study as the blood pressure was not measured during each visit so it is uncertain as to when his blood pressure decreased to almost normal levels. More studies need to be done and careful evaluations and measurements need to be taken to determine if there is in fact, a correlation between C1 and hypertension and if future chiropractic patients can expect similar results over an established period of time.

## References

1. Gu Q, Paulose-Ram R, Dillon C and Burt V. Antihypertensive medication use among US adults with hypertension. *Circulation* 2006, 113:213-221.
2. Mateos-Cceres P, Zamorano-Leon J, Rodriguez-Sierra P, et al. New and old mechanisms associated with hypertension in the elderly. *Int J Hypertens* 2011; Vol 2012, article ID 150107.
3. Stafford R, Monti V, Furberg C and Ma J. Long-term and short-term changes in antihypertensive prescribing by office-based physicians in the united states. *Hypertension* 2006; 48:213-218.
4. Hajjar I, Kotchen T. Trends in prevalence, awareness, treatment, and control of hypertension in the United States, 1998-2000. *JAMA* 2003; 290(2): 199-206.

5. Chobanian A, Bakris G, Black H, et al. Seventh report of the joint national committee on prevention, detection, evaluation, and treatment of high blood pressure. *Hypertension* 2003; 42:1206-1252.
6. Cutler J, Sorlie P, Wolz M, et al. Trends in hypertension prevalence, awareness, treatment, and control rates in United States adults between 1988-1994 and 1999-2004. *Hypertension* 2008; 52: 818-827.
7. Bakris G, Dickholtz M, Meyer PM, Kravitz G, et al. Atlas vertebra realignment and achievement of arterial pressure goal in hypertensive patients: a pilot study. *J Hum Hypertens.* 2007;21(5):347–52.
8. Eriksen K, Rochester R, Hurwitz E. Symptomatic reactions, clinical outcomes and patient satisfaction associated with upper cervical chiropractic care: a prospective, multicenter, cohort study. *BMC Musculoskeletal Disorders* 2011, 12:219.
9. Reis D. The brain and hypertension: reflections on 35 years of inquiry into the neurobiology of the circulation. *Circulation.* 1984; 70(5 pt 2):III31-45.
10. Reis D, Morrison S, Ruggiero D. The C1 area of the brainstem in tonic and reflex control of blood pressure. State of the art lecture. *Hypertension.* 1988 Feb;11(2 Pt 2):I8-13.
11. Guertzenstein P, Lopes O. Cardiovascular responses evoked from the nicotine-sensitive area on the ventral surface of the medulla oblongata in the cat. *J. Physiol* 1984; 347: 345-360.
12. Dampney R. Blood pressure regulation by C1 neurons in the rostral ventrolateral medulla: new light on the subject. *J Physiol* 2009; 587.23: 5513.
13. Akimura T, Furutani Y, Jimi Y, Saito K, Kashiwagi S, Kato S et al. Essential hypertension and neurovascular compression at the ventrolateral medulla oblongata: MR evaluation. *Am J Neuoradiol* 1995; 16: 401-405.
14. Dampney R, Goodchild A, Tan E. Vasopressor neurons in the rostral ventrolateral medulla of the rabbit. *J Auton Nerv Syst* 1985; Nov;14(3):239-54.
15. Budgell BS. Reflex effects of subluxation: the autonomic nervous system. *J Manipulative Physiol Ther* 2000; 23(2): 104–106.
16. Cassidy J, Boyle, Cote P, He Y, Hogg-Johnson S, Silver F, Bondy S. Risk of vertebrobasilar stroke and chiropractic care: results of a population based case-control and case-crossover study. *J Manipulative Physiol Ther* 2009; 32(2 Suppl):S201-208.

# Figures

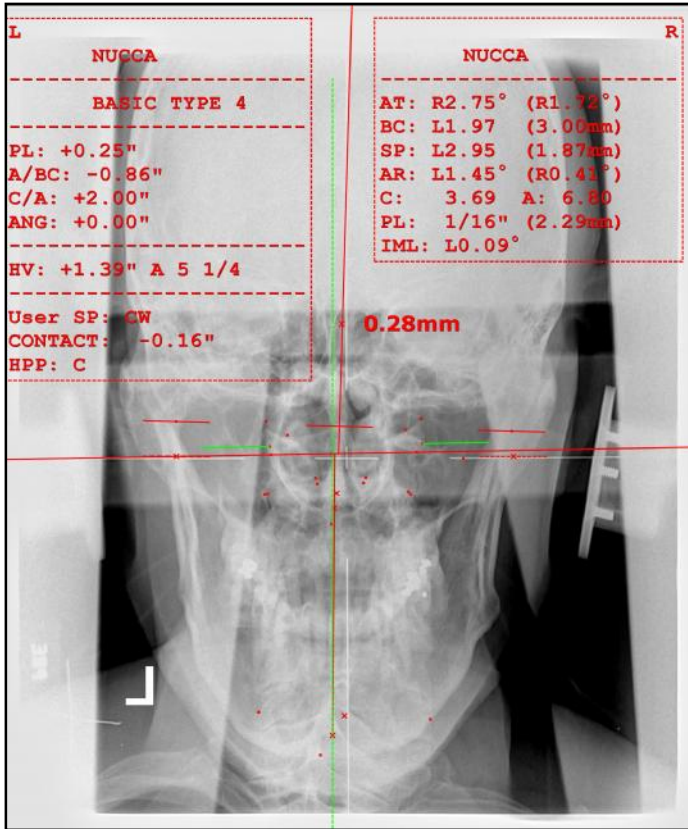


Figure 1. Pre Nasium

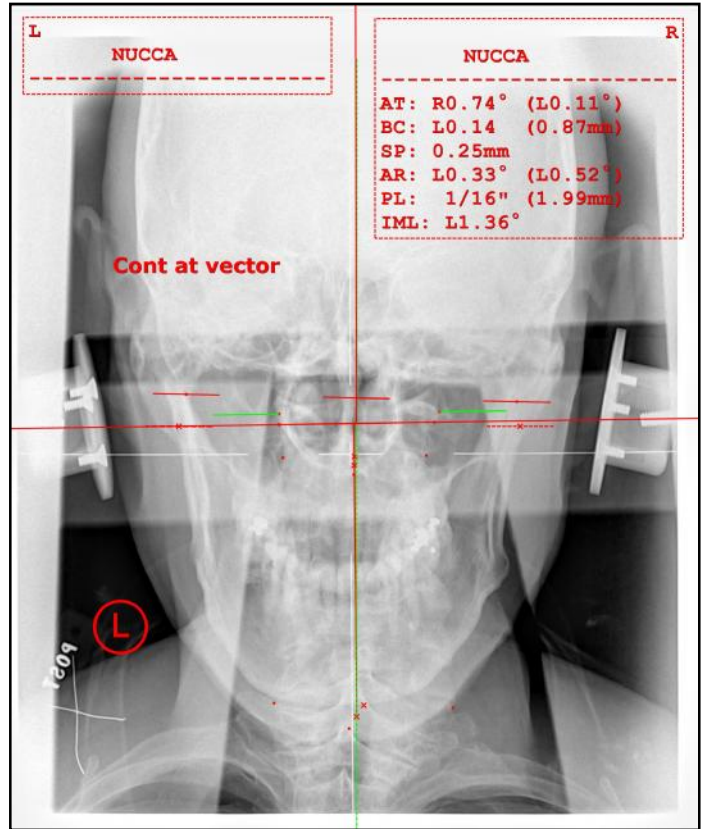


Figure 3. Post Nasium

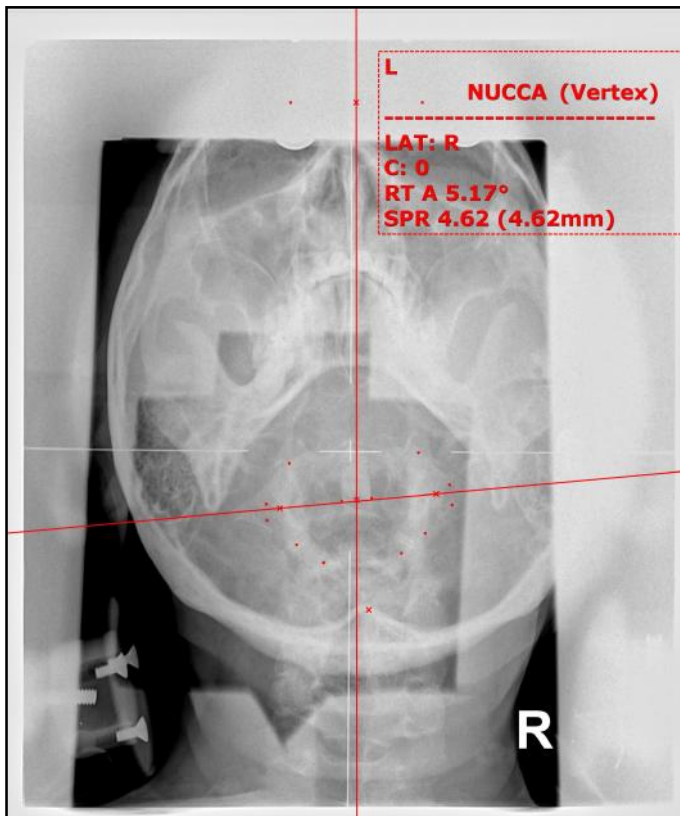


Figure 2. Pre Vertex

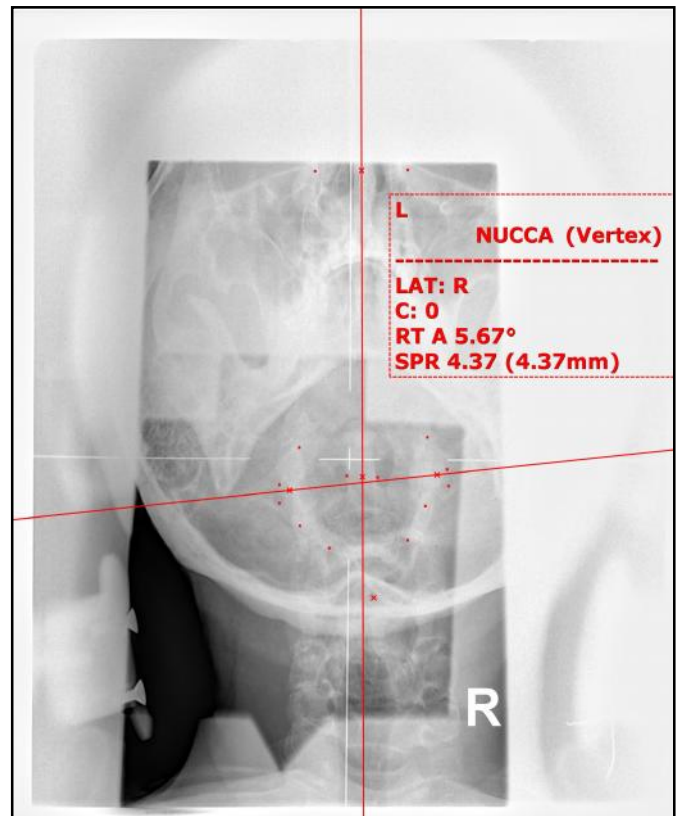

Figure 4. Post Vertex